



## Research paper

# Efficacy of imidacloprid 10%/moxidectin 2.5% spot on (Advocate®, Advantage Multi®) and doxycycline for the treatment of natural *Dirofilaria immitis* infections in dogs

Marco Genchi<sup>a</sup>, Alice Vismarra<sup>a,\*</sup>, Chiara Lucchetti<sup>a</sup>, Antonio Viglietti<sup>b</sup>, Serena Crosara<sup>a</sup>, Giacomo Gnudi<sup>a</sup>, Cecilia Quintavalla<sup>a</sup>, Roland Schaper<sup>c</sup>, Laura Kramer<sup>a</sup>

<sup>a</sup> Department of Veterinary Science, University of Parma, Parma, Italy

<sup>b</sup> Ambulatorio Veterinario Dr. Viglietti-Dr.s.s. Piazza, Carloforte, Italy

<sup>c</sup> Bayer Animal Health GmbH, Leverkusen, Germany



## ARTICLE INFO

## Keywords:

*Dirofilaria immitis*

Dog

Moxidectin

Doxycycline

Melarsomine dihydrochloride

## ABSTRACT

Heartworm infection (also known as dirofilariosis due to *Dirofilaria immitis*) in dogs causes chronic pulmonary disease that, if left untreated, can lead to right-side congestive heart failure. Currently, the only registered drug for adulticide therapy in dogs with heartworm disease (HWD) is melarsomine dihydrochloride. The recent targeting of the bacterial endosymbiont *Wolbachia*, through antibiotic therapy of the infected host, has offered an interesting alternative for the treatment of HWD. Recent reports of the adulticide activity of an ivermectin/doxycycline combination protocol has lead the American Heartworm Society (AHS) to include in its guidelines that, in cases where arsenical therapy is not possible or is contraindicated, a monthly heartworm preventive along with doxycycline for a 4-week period might be considered. In the present study, 20 dogs with confirmed natural *D. immitis* infection were included following owner consent. Fourteen dogs were treated with a topical formulation containing 10% w/v imidacloprid and 2.5% w/v moxidectin (Advocate®, Advantage Multi®, Bayer), monthly for nine months, associated to doxycycline (10 mg/kg/BID) for the first 30 days. Six dogs were treated with melarsomine (Immiticide®, Merial) (2.5 mg/kg) at enrollment, followed one month later by two injections 24 h apart.

The presence of circulating antigens and the number of microfilariae (mf) were evaluated at the moment of enrollment and then at 1, 2, 3, 4, 5, 6, 7, 8, 12, 18, 24 months post enrollment. Echocardiogram and radiographs were performed at month 0, 6, 12, 18, 24.

Monthly moxidectin combined with 30 days of doxycycline eliminated circulating microfilariae within one month, thus breaking the transmission cycle very quickly. Furthermore, dogs treated with the combination protocol started to become negative for circulating antigens at 4 months from the beginning of treatment and all except one were antigen negative at 9 months. All dogs treated with melarsomine were antigen negative by 5 months from the beginning of the treatment. No dogs showed worsening of pulmonary patterns or criteria indicative of pulmonary hypertension 12 to 24 months after. For the criteria mf concentration, antigen concentration, radiography and echocardiography at 12, 18 and 24 months the non-inferiority for the moxidectin group could be proven for a non-inferiority margin of 15% for the rate difference. Dogs treated with moxidectin and doxycycline became negative for microfilariae and antigens sooner when compared to melarsomine in the present study and to dogs treated with doxycycline combined with ivermectin in studies previously published.

## 1. Introduction

*Dirofilaria immitis* is a vector-borne filarial nematode that causes canine heartworm disease (HWD) in many areas of the world. The infection is transmitted by mosquitos and appears to be spreading into previously unaffected areas both in the United States and Europe, due

to global warming and movement of infected dogs (AHS incidence maps, 2016; Drake and Wiseman, 2018; Genchi et al., 2009; Penezić et al., 2014). If left untreated, dogs with HWD develop right-side congestive heart failure due to a chronic rise in pulmonary pressure (ESDA guidelines, 2017). Melarsomine dihydrochloride is currently the only drug approved for adulticidal treatment, but issues related to cost,

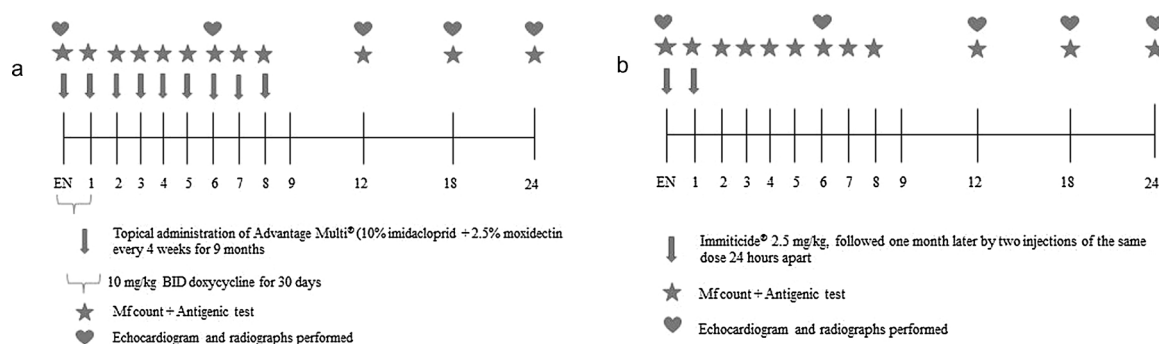
\* Corresponding author at: Department of Veterinary Sciences, University of Parma, Via del Taglio 10, 43126 Parma, Italy.

E-mail address: [alice.vismarra@unipr.it](mailto:alice.vismarra@unipr.it) (A. Vismarra).

<https://doi.org/10.1016/j.vetpar.2019.07.011>

Received 16 May 2019; Received in revised form 25 July 2019; Accepted 26 July 2019

0304-4017/ © 2019 Elsevier B.V. All rights reserved.



**Fig. 1.** a. Treatment regimen for moxidectin/doxycycline; b. Treatment regimen for melarsomine. (EN: enrollment; mf: microfilariae).

availability and side-effects of treatment have led to the search for alternative therapeutic protocols (Kramer et al., 2018).

Several studies in both experimentally- and naturally- infected dogs have reported the adulticide effect of a combination of macrocyclic lactones and doxycycline against *D. immitis*, showing that these protocols are safe and effective (Bazzocchi et al., 2008; Bendas et al., 2017; Grandi et al., 2010; Mavropoulou et al., 2014; Savadelis et al., 2017). Doxycycline targets the endosymbiont *Wolbachia*, whose reduction leads to worm infertility and death (Kramer et al., 2007). This activity, combined with the known detrimental effects of macrocyclic lactones, eliminates adult worms and lessens the inflammatory reaction against dead and dying worms (Kramer et al., 2011). The American Heartworm Society (AHS) and the European Society of Dirofilariosis and Angiostromylosis (ESDA) currently include in their guidelines that in cases where treatment with melarsomine is not possible or is contraindicated, a monthly macrocyclic lactone along with doxycycline for a 4-week period might be considered (AHS guidelines, 2018; ESDA guidelines, 2017).

The aim of the present study was to evaluate the adulticide effect of a combination of moxidectin and doxycycline in dogs naturally-infected with *D. immitis* from two endemic areas of Italy and to compare efficacy to melarsomine.

## 2. Materials and methods

### 2.1. Study design

The present study evaluated the efficacy of 10% w/v imidacloprid and 2.5% w/v moxidectin (Advocate®, Advantage Multi®, Bayer) in combination with doxycycline (Ronaxan®, Merial). A melarsomine group of dogs was treated with melarsomine dihydrochloride (Immiticide®, Merial), according to the three step protocol. Briefly, one dose of melarsomine (2.5 mg/kg body weight) was administered at enrollment and was followed one month later by two further doses, 24 h apart.

### 2.2. Animals

A total of 20 dogs with naturally acquired HWD were enrolled from two Italian provinces endemic for *D. immitis*, Parma (Emilia-Romagna region, north of Italy) and Carloforte (Carbonia-Iglesias province, island of Sardinia). Inclusion criteria targeted dogs of any breed/sex, weighing at least 1 kg of bodyweight, being > 5 months of age and not having been treated within 2 months prior with any macrocyclic lactone or doxycycline. Dogs were considered positive for infection when a circulating antigen test (PetChek® HTWM PF, IDEXX) and/or microfilariae (modified Knott's test) was positive for *D. immitis*. Owners' consent was obtained prior to any study activities.

### 2.3. Treatment protocols

Treatment protocols are summarized in Fig. 1a and b. Briefly, topical administration of 10% imidacloprid + 2.5% moxidectin (Advocate®) was administered to 14 dogs once a month for 9 consecutive months together with doxycycline (10 mg/kg BW, BID) for the first 30 days (Fig. 1a). For the melarsomine group, melarsomine dihydrochloride (Immiticide®) was administered at the moment of enrollment, 2.5 mg/kg BW, followed one month later by two injections of the same dose 24 h apart to six dogs (Fig. 1b).

### 2.4. Parasitological evaluation

Blood samples were collected once a month for nine months and then at 12, 18, 24 months from all dogs enrolled in the study, apart from three dogs in the melarsomine group that did not present at one or two control visits.

Microfilarial concentration was determined in 1 ml of blood with the modified Knott's test (Balbo and Panichi, 1968). The number of microfilariae (mf) was expressed as n° of mf /1 ml blood. Serum samples were tested for circulating antigens using PetChek® HTWM PF (IDEXX), following the manufacturer's instructions. Antigen concentration was also evaluated reading the plates with a spectrophotometer at 650 nm. The cut-off was defined as the average value of all the negative controls provided by the manufacturer of the kits used during in each antigenic test session + 3SD. In particular, nine testing sessions were done and all the samples with OD values higher than the cut-off were considered as positive. The mean OD value of all the dogs for each time point was considered in order to compare the decrease in antigen concentration between the two treatment groups.

### 2.5. Thoracic radiography and cardiac ultrasound

Thoracic radiography in double orthogonal views and cardiac ultrasound were carried out at months 0, 6, 12, 18 and 24. Scoring of interstitial lung patterns and haemodynamic parameters was according to Mavropoulou et al. (2014). The following scores were used: lung pattern 0 (normal) to 3 (severe) and cardiac ultrasound 0 (normal) to 3 (severe pulmonary hypertension) (see Table 1).

At the same time as blood sampling, dogs underwent a physical examination to verify their health status.

### 2.6. Statistical analyses

The statistical analysis was performed by Dipl.-Stat. Marion Ocak, MD research, Munich, Germany. The data were supplied in electronic form (MS EXCEL, file name "Bayer\_24 months\_summary incl table-s.docx", ~101 kilobytes, dated 12. April 2019) for the statistical analysis. After changing the titles of the rows according to idv-standard (idv computer programs were used for the analysis), the data for

**Table 1**  
Score system applied for thoracic radiographs and cardiac ultrasound evaluation (Mavropoulou et al., 2014).

Score	Pulmonary interstitial disease (thoracic radiography)			Clinical evaluation
	0	1	2	
	Normal	Mild unstructured interstitial lung pattern in the caudal lobe	More diffuse and uniform unstructured interstitial lung pattern	
	Diffuse pulmonary densities, signs compatible with thrombo-embolism/pneumonia			
Score	Pulmonary hypertension (echocardiography)			Clinical evaluation
	0	1	2	
	Normal (AT <sup>a</sup> > 64 ms; AT/ET <sup>b</sup> ratio > 0.42 ms) TRV < 2.8 m/s	Slight alterations (AT/ET = 0.42–0.26 ms) TRV < 2.8 m/s	Moderate alterations (AT ≤ 45 ms; AT/ET ≤ 0.25; TRV <sup>c</sup> ≥ 2.8 m/s)	
	Marked alterations (moderate/severe pulmonary hypertension: TRV > 3.57 m/s)			

<sup>a</sup> Acceleration time.

<sup>b</sup> Ejection time.

<sup>c</sup> Tricuspid valve regurgitation velocity.

analysis were transferred to the analysis programs according to idv-SOPs by means of the validated idv Excel-transfer.

The analysis was performed with the validated program Report Version 6.7 and Testimate Version 6.5 from IDV Gauting (validation of software, hardware and user according to FDA 21 CFR Part 11. All evaluation steps were completely documented.

Continuous variables will be described by number of valid cases, mean, median, standard deviation, quartiles, minimum and maximum. Categorical variables will be described by number of valid cases, frequency and percentage.

The study has been conducted as a non-inferiority study. The statistical analysis was performed according to the 2 step approach based on Bauer and Köhne (1994, adaptive design), planned with a minimum of eight patients in each treatment group. In the melarsomine group were now only six animals. Reasons and explanation will be provided.

Non parametric tests ( $2 \times 2$  Test) were calculated to judge differences or equality of the two treatment groups. The non-inferiority is defined for a non-inferiority-margin of 15% for the rate difference.

### 3. Results

#### 3.1. Animals and treatment groups

Fourteen dogs were treated with the combination of 10% w/v imidacloprid and 2.5% w/v moxidectin/doxycycline combination and 6 with melarsomine dihydrochloride as melarsomines. Table 2 reports the age and sex of dogs in the two groups. Four females and 10 males, with an average age of 7 years, were treated with moxidectin/doxycycline. The group treated with melarsomine consisted of males only, with an average age of 5.5 years. Due to lack of owner consent it was not possible to enroll 8 animals as planned for the statistical analysis, however this had no influence on the results.

#### 3.2. Parasitological evaluation

##### 3.2.1. Microfilariaemia

Thirteen of the fourteen dogs in the moxidectin/doxycycline group had circulating microfilariae at the moment of enrollment. Ten became negative after 1 month of treatment, while the remaining 3 had 4 mf/ml of blood at day 30. The moxidectin/doxycycline combination induced a consistent reduction in mf count with a 99.9% efficacy already after one month (Fig. 2). Only two of the six melarsomine dogs treated with melarsomine had circulating mf at enrollment. One became negative at three months from the beginning of the treatment, while the other required 9 months to become non-microfilaremic. This was not unexpected as melarsomine is not active against microfilariae.

For microfilaraemia at 12, 18 and 24 months, non-inferiority of the moxidectin/doxycycline group vs. the melarsomine group could be proven (100.00% vs. 100.00%).

##### 3.2.2. Antigenemia

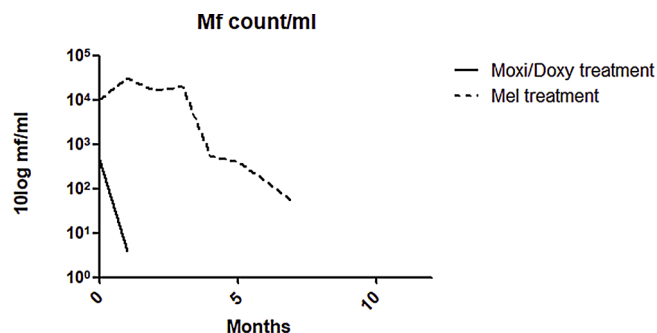
All dogs treated with moxidectin/doxycycline except one were antigen negative by 9 months post-enrollment. One dog treated with melarsomine became antigen negative at three months post enrollment (p.e), three at four months, one at five and one at six months p.e. Fig. 3 reports the average OD obtained from dogs treated with moxidectin/doxycycline and melarsomine at each time point. OD values were considered positive if higher than 0.08 (cut-off). Dogs treated with melarsomine showed first a rise in OD values, followed by a rapid reduction in antigen concentration. Reduction of antigen concentration was more gradual in dogs treated with moxidectin/doxycycline.

For antigenemia at 12, 18 and 24 months, non-inferiority of the moxidectin/doxycycline group vs. the melarsomine group could be proven (100.00% vs. 83.33%, 100.00% vs. 100.00% and 100.00% vs. 100.00%)

**Table 2**

Enrolled dogs (moxi/doxy: moxidectin + doxycycline; mel: melarsomine dihydrochloride).

Group/No. Animals	#/sex	Age (mean years)
MOXI/DOXY (tot. 14)	4/F 10/M	2–12 (mean 6.5 years)
MEL (tot. 6)	6 /M	3–8 (mean 5.5 years)



**Fig. 2.** Number of mf/ml (average value for positive dogs) expressed ad log10 after treatment with moxidectin/doxycycline (moxi/doxy) vs. melarsomine (mel).

### 3.3. Thoracic radiographs

Four dogs in the moxidectin/doxycycline group had an interstitial lung pattern score of 1 at enrollment, while the remaining 10 had a score of 0. At 6 months from the beginning of treatment, one dog with a score of 0 at enrollment had a score of 1. Of the four dogs with a score of 1 at enrollment, 3 improved (score of 0) while one remained 1. At months 12, 18 and 24, all dogs treated with moxidectin/doxycycline had a score of 0.

All dogs in the melarsomine group had a score of 0 at enrollment and at 6 months. Two dogs showed a score of 1 at 12 months. At months 18 and 24 months, all dogs from the melarsomine group had a score of 0 (see Table 3).

For thoracic radiographs at 12, 18 and 24 months non-inferiority of the moxidectin/doxycycline group vs. the melarsomine group could be proven (100.00% vs. 66.67%, 100.00% vs. 100.00% and 100.00% vs. 100.00%).

### 3.4. Cardiac ultrasound

Two dogs in the moxidectin/doxycycline group had a cardiac ultrasound score of 1 at enrollment, while all others had a score of 0. At months 6, 12, 18 and 24, all dogs from this group had a score of 0. Two dogs in the melarsomine group had a score of 1 at enrollment, while all others had a score of 0. At 6 months, the two dogs with 1 at enrollment were still scored at 1, while another normal dog at enrollment was scored with mild alterations. At months 12, 18 and 24, all dogs from the melarsomine group had a score of 0 (as shown in Table 3).

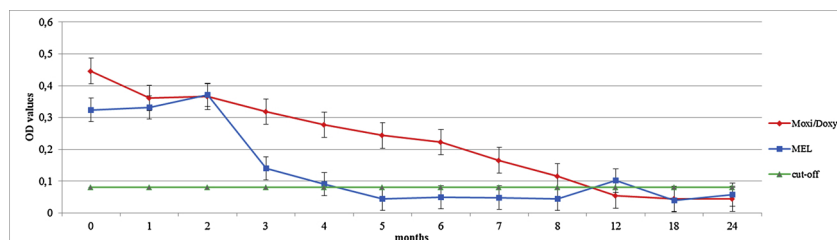
For cardiac ultrasound at 12, 18 and 24 months, non-inferiority of the moxidectin/doxycycline group vs. the melarsomine group could be proven (100.00% vs. 100.00%).

## 4. Discussion

In the present study we evaluated the adulticide efficacy of a combination of moxidectin and doxycycline in dogs naturally infected with *D. immitis* and compared microfilariaemia, antigenemia and cardiorespiratory parameters in dogs treated with melarsomine. Melarsomine was administered with the three-step protocol. It has been shown that this protocol is safer and more effective for adulticide treatment in dogs compared to the two-step protocol reported on the product label, independent of the dog's clinical status (Keister et al., 1992; Vezzoni et al., 1992). Even though the three step protocol was proposed, owner consent was limited for melarsomine, explaining the low number (6) of dogs in this treatment group. It is likely that the absence of pre-treatment with doxycycline and a macrocyclic lactone before melarsomine administration, as recommended by the most recent guidelines of the American Heartworm Society (2018) and of the European Society for Dirofilariosis and Angiostrongylosis (2017), led owners to refuse enrollment. Indeed, as reported by Genchi et al. (2019), combination protocols with doxycycline and MLs are becoming increasingly popular in Italy.

Results of the present study confirm the adulticide effects of moxidectin combined with doxycycline previously reported by Savadelis et al. (2017) in experimentally infected dogs and by Bendas et al. (2017) in naturally infected dogs in Brazil. In the present study, the adulticide effect was confirmed through serology without pre-heating the serum samples and negative serology of non-heated samples was considered as definitive cure. Indeed, several recent studies have questioned if heat treatment actually results in reliable and specific seroconversion in dogs that are negative without heating serum. Savadelis et al. (2018) reported that positive results of heat-treated sera from *D. immitis*-experimentally infected dogs were not confirmed at necropsy. Venco et al. (2017) showed that heat treatment caused positive antigen test results of samples from a wide variety of parasites and parasitic infections, including mono-infections with *Dirofilaria repens*, the aetiological agent of subcutaneous dirofilariosis which is widespread in many European countries. Ciucă et al. (2016) reported that heating of serum samples from dogs with *D. repens* caused false positive results and concluded that where *D. repens* is endemic, heating of samples is not currently recommended.

In the present study, moxidectin/doxycycline treatment induced a gradual reduction in adult worm antigen concentration from three months onward from the beginning of treatment, with all dogs, except one, becoming negative at 9 months. This gradual decline in circulating antigens is similar to that reported by Savadelis et al. (2017). This may be due to the gradual loss of intrauterine content and a slow decrease in antigen release while worms are dying, as compared to the massive release likely consequent to melarsomine-induced death, where a sudden and rapid decline in antigenemia was observed at 3–4 months. In naturally infected dogs, we cannot exclude that immature parasites that are migrating during the 9-month treatment regime may also have arrived as adults and then subsequently died. The present study would also indicate that the combination of moxidectin/doxycycline has superior adulticide efficacy compared to ivermectin/doxycycline. In a previous study in naturally-infected dogs treated with doxycycline for



**Fig. 3.** Circulating antigens evaluation after moxidectin/doxycycline and melarsomine treatments.

**Table 3**  
Individual scores for echocardiographic and thoracic radiographic evaluation of dogs treated with moxi/doxy and mel (EN:enrollment).

Thoracic radiography in double orthogonal scores					
moxi + doxy		score			
dogs	EN	6 months	12 months	18 months	24 months
1	1	0	0	0	0
2	1	0	0	0	0
3	1	0	0	0	0
4	1	1	0	0	0
5	0	1	0	0	0
6	0	0	0	0	0
7	0	0	0	0	0
8	0	0	0	0	0
9	0	0	0	0	0
10	0	0	0	0	0
11	0	0	0	0	0
12	0	0	0	0	0
13	0	0	0	0	0
14	0	0	0	0	0

MEL					
		score			
dogs	EN	6 months	12 months	18 months	24 months
1	0	0	1	0	0
2	0	0	1	0	0
3	0	0	0	0	0
4	0	0	0	0	0
5	0	0	0	0	0
6	0	0	0	0	0

Cardiac ultrasound scores					
moxi + doxy		score			
dogs	EN	6 months	12 months	18 months	24 months
1	1	0	0	0	0
2	1	0	0	0	0
3	0	0	0	0	0
4	0	0	0	0	0
5	0	0	0	0	0
6	0	0	0	0	0
7	0	0	0	0	0
8	0	0	0	0	0
9	0	0	0	0	0
10	0	0	0	0	0
11	0	0	0	0	0
12	0	0	0	0	0
13	0	0	0	0	0
14	0	0	0	0	0

MEL					
		score			
dogs	EN	6 months	12 months	18 months	24 months
1	1	1	0	0	0
2	1	1	0	0	0
3	0	0,5	0	0	0
4	0	0	0	0	0
5	0	0	0	0	0
6	0	0	0	0	0

30 days and oral ivermectin every 15 days for 6 months, approximately 73% of dogs became antigen-negative by 10 months from the beginning of treatment (Grandi et al., 2010). It has been shown that topically applied moxidectin accumulates in the steady state and maintains effective drug levels in the body even after 28 days after the last administration (Bowman et al., 2016). This translates into a greater effectiveness both against heartworms and against new infections with susceptible isolates (when used as a preventive). Milbemycins are structurally similar to avermectins, but show differences in interactions with glutamate-gated chloride channels and in accumulation in fat

tissue. Moxidectin (a milbemycin), is characterized by a longer half-life, by a larger volume of distribution and slower clearance rate than ivermectin (an avermectin) in different species (Prichard et al., 2012). Moreover, ivermectin is actively transported out of cells by ABC transporters. Indeed, the integrity of the disaccharide moiety present on avermectins plays a determining role in the affinity for P-glycoproteins (PgPs), while moxidectin kinetics are not dependent on PgPs or other ABC transporters (Kiki-Mvouaka et al., 2010; Lespine et al., 2007). This may contribute to higher accumulation of the drug in the worm, leading to greater efficacy of moxidectin/doxycycline combinations compared to ivermectin/doxycycline. Lastly, as reported by Savadelis et al. (2017) the greater efficacy of moxidectin in combination with doxycycline, may be due to the higher amount of moxidectin administered (minimum dose of 2.5 mg/kg) compared to ivermectin.

The decline in circulating mf was dramatic in moxidectin/doxycycline treated dogs. There were so few mf in the two dogs that were still positive at day 30 to consider them as inconsequential in terms of reservoir capacity. The rapid reduction in mf is extremely important in breaking the life cycle of the parasite. Interestingly, the present protocol was superior in microfilaricidal efficacy than the combination of ivermectin/doxycycline reported previously by Grandi et al. (2010), where the reduction in circulating microfilariae was relevant from day 30 after treatment (37.5% of dogs negative) but reached 100% by day 90. As expected, dogs treated here with melarsomine continued to be microfilarimic for several months, given that melarsomine is not active against microfilariae, while moxidectin is.

Here, we also evaluated cardio-pulmonary parameters in order to evaluate the effect of both treatment regimens on dogs' clinical status. Of the dogs that showed inflammatory interstitial patterns alterations at enrollment, progression of disease was similar in the two treatment groups and all dogs were cleared of pulmonary abnormalities by 18 months from the beginning of treatment. However, dogs treated with the moxidectin/doxycycline combination achieved a score of 0 earlier than dogs treated with melarsomine. This is likely due to the elimination of *Wolbachia*, thanks to the action of doxycycline, and the dramatic reduction of pro-inflammatory antigen mass, previously reported in worms from experimentally treated animals (Kramer et al., 2011). Similar to that described for interstitial inflammation, dogs showing signs of pulmonary hypertension at enrollment and treated with a combination of moxidectin/doxycycline improved sooner than dogs treated with melarsomine. Results of the present study are similar to those reported by Mavropoulou et al. (2014) in naturally-infected dogs treated with ivermectin/doxycycline, in which 84% of treated dogs either progressively improved parameters indicative of pulmonary hypertension/interstitial inflammation or, following slight worsening, resolved all signs by the end of the study. However, dogs were evaluated only until 10 months from the beginning of treatment. In the present study, dogs were followed for two years and complete clinical and parasitological cure was confirmed. The only other previous study to follow dogs for this long a period of time after adulticide therapy is Venco et al. (2004), who evaluated naturally-infected dogs treated with monthly ivermectin.

The results of a recent survey of veterinary facilities in Italy (Genchi et al., 2019) reported that 35% of the facilities used melarsomine for adulticide therapy, while 29% used a macrocyclic lactone combined with doxycycline, indicating that the alternative protocol is becoming increasingly employed as a valid alternative when melarsomine dihydrochloride is not available, not affordable by dog owners or contraindicated. Studies like the present one are thus important to assist practitioners in choosing the best option for their clients and their patients. Future studies comparing the currently recommended adulticide treatment (pre-treatment with doxycycline and a macrocyclic lactone, followed by melarsomine) with the combined doxycycline/ML protocol would be of particular interest.

## 5. Conclusion

The combination of moxidectin/doxycycline is effective in eliminating microfilariae and adult heartworms. The protocol is non-inferior to melarsomine at 12, 18 and 24 months from the beginning of treatment. Dogs tolerate the regime well.

## Declaration of Competing Interest

RS is currently employed by Bayer Animal Health GmbH. The remaining authors declare no conflict of interests.

## Funding

The present study has been funded by Bayer Animal Health GmbH, Leverkusen, Germany.

## Acknowledgement

The authors would like to thank Dr. Chiara Cattabiani for excellent technical assistance.

## References

- American Heartworm Society, 2016. Heartworm incidence maps. Available at: <https://www.heartwormsociety.org/pet-owner-resources/incidence-maps>.
- American Heartworm Society, 2018. The AHS guidelines, update. Available at: <https://www.heartwormsociety.org/veterinary-resources/veterinary-education/ahs-board-speaks-out/510-the-ahs-guidelines-2018-updates>.
- Balbo, T., Panichi, M., 1968. La filariosi del cane. *La Nuova Vet.* 44, 18–32 (in Italian).
- Bauer, P., Köhne, K., 1994. Evaluation of experiments with adaptive interim analysis. *Biometrics* 50, 1029–1041.
- Bazzocchi, C., Mortarino, M., Grandi, G., Kramer, L.H., Genchi, C., Bandi, C., Genchi, M., Sacchi, L., McCall, J.W., 2008. Combined ivermectin and doxycycline treatment has microfilaricidal and adulticidal activity against *Dirofilaria immitis* in experimentally infected dogs. *Int. J. Parasitol.* 38 (12), 1401–1410.
- Bendas, A.J.R., Mendes-de-Almeida, F., Von Simson, C., Labarthe, N., 2017. Heat pretreatment of canine samples to evaluate efficacy of imidacloprid + moxidectin and doxycycline in heartworm treatment. *Parasites Vectors* 10 (246).
- Bowman, D.D., Grazette, A.R., Basel, C., Wang, Y., Hostetler, J.A., 2016. Protection of dogs against canine heartworm infection 28 days after four monthly treatments with Advantage Multi (R) for dogs. *Parasites Vectors* 9 (12).
- Ciucă, L., Genchi, M., Kramer, L., Mangia, C., Miron, L.D., Prete, L.D., Maurelli, M.P., Cringoli, G., Rinaldi, L., 2016. Heat treatment of serum samples from stray dogs naturally exposed to *Dirofilaria immitis* and *Dirofilaria repens* in Romania. *Vet. Parasitol.* 225, 81–85.
- Drake, J., Wiseman, S., 2018. Increasing incidence of *Dirofilaria immitis* in dogs in USA with focus on the southeast region 2013–2016. *Parasites Vectors* 11 (39).
- European Society of Dirofilariosis and Angiostrongylosis (ESDA), 2017. Guidelines for clinical management of canine heartworm disease. Available at: <https://www.esda.vet/wp-content/uploads/2017/11/GUIDELINES-FOR-CLINICAL-MANAGEMENT-OF-CANINE-HEARTWORM-DISEASE.pdf>.
- Genchi, C., Rinaldi, L., Mortarino, M., Genchi, M., Cringoli, G., 2009. Climate and *dirofilaria* infection in Europe. *Vet. Parasitol.* 163 (4), 286–292.
- Genchi, M., Rinaldi, L., Venco, L., Cringoli, G., Vismarra, A., Kramer, L., 2019. *Dirofilaria immitis* and *D. repens* in dog and cat: a questionnaire study in Italy. *Vet. Parasitol.* 267, 26–31.
- Grandi, G., Quintavalla, C., Mavropoulou, A., Genchi, M., Gnudi, G., Bertoni, G., Kramer, L., 2010. A combination of doxycycline and ivermectin is adulticidal in dogs with naturally acquired heartworm disease (*Dirofilaria immitis*). *Vet. Parasitol.* 169 (3–4), 347–351 (Erratum in: *Vet Parasitol.* 2011; 177(1–2), 196. Dosage error in published abstract).
- Keister, D.M., Dzimiński, M.T., McTier, T.L., McCall, J.W., Brown, J., 1992. Dose selection and confirmation of RM 340, a new filaricide for the treatment of dogs with immature and mature *Dirofilaria immitis*. *Proceedings of the Heartworm Symposium* 92 225–229.
- Kiki-Mvuka, S., Ménez, C., Borin, C., Lyazrhi, F., Foucaud-Vignault, M., Dupuy, J., Collet, X., Alvinerie, M., Lespine, A., 2010. Role of P-glycoprotein in the disposition of macrocyclic lactones: a comparison between ivermectin, eprinomectin, and moxidectin in mice. *Drug Metab. Dispos.* 38 (4), 573–580.
- Kramer, L., McCall, J.W., Grandi, G., Genchi, C., 2007. Wolbachia and its importance in veterinary filariasis. *Issues Infect. Dis.* 5, 124–132.
- Kramer, L., Grandi, G., Passeri, B., Gianelli, P., Genchi, M., Dzimiński, M.T., Supakorndej, P., Mansour, A.M., Supakorndej, N., McCall, S.D., McCall, J.W., 2011. Evaluation of lung pathology in *Dirofilaria immitis*-experimentally infected dogs treated with doxycycline or a combination of doxycycline and ivermectin before administration of melarsomine dihydrochloride. *Vet. Parasitol.* 176 (4), 357–360.
- Kramer, L., Crosara, S., Gnudi, G., Genchi, M., Mangia, C., Viglietti, A., Quintavalla, C., 2018. Wolbachia, doxycycline and macrocyclic lactones: New prospects in the treatment of canine heartworm disease. *Vet. Parasitol.* 254, 95–97.
- Lespine, A., Martin, S., Dupuy, J., Roulet, A., Pineau, T., Orłowski, S., Alvinerie, M., 2007. Interaction of macrocyclic lactones with P-glycoprotein: structure–affinity relationship. *Eur. J. Pharm. Sci.* 30 (1), 84–94.
- Mavropoulou, A., Gnudi, G., Grandi, G., Volta, A., Kramer, L.H., Quintavalla, C., 2014. Clinical assessment of post-adulticide complications in *Dirofilaria immitis*-naturally infected dogs treated with doxycycline and ivermectin. *Vet. Parasitol.* 205 (1–2), 211–215.
- Penezić, A., Selaković, S., Pavlović, I., Ćirović, D., 2014. First findings and prevalence of adult heartworms (*Dirofilaria immitis*) in wild carnivores from Serbia. *Parasitol. Res.* 113 (9), 3281–3285.
- Prichard, R., Ménez, C., Lespine, A., 2012. Moxidectin and the avermectins: consanguinity but not identity. *Int. J. Parasitol. Drugs Drug Resist.* 2, 134–153.
- Savadelis, M.D., Ohmes, C.M., Hostetler, J.A., Settje, T.L., Zolynas, R., Dzimiński, M.T., Moorhead, A.R., 2017. Assessment of parasitological findings in heartworm-infected beagles treated with Advantage Multi® for dogs (10% imidacloprid + 2.5% moxidectin) and doxycycline. *Parasites Vectors* 10 (245).
- Savadelis, M.D., Roveto, J.L., Ohmes, C.M., Hostetler, J.A., Settje, T.L., Dzimiński, M.T., Moorhead, A.R., 2018. Evaluation of heat-treating heartworm-positive canine serum samples during treatment with Advantage Multi® for dogs and doxycycline. *Parasites Vectors* 11 (98).
- Venco, L., McCall, J.W., Guerrero, J., Genchi, C., 2004. Efficacy of long-term monthly administration of ivermectin on the progress of naturally acquired heartworm infections in dogs. *Vet. Parasitol.* 124 (3–4), 259–268.
- Venco, L., Manzocchi, S., Genchi, M., Kramer, L.H., 2017. Heat treatment and false-positive heartworm antigen testing in ex vivo parasites and dogs naturally infected by *Dirofilaria repens* and *Angiostrongylus vasorum*. *Parasites Vectors* 10 (476).
- Vezzoni, A., Genchi, C., Raynaud, J.P., 1992. Adulticide efficacy of RM 340 in dogs with mild and severe natural infections. *Proceedings of the Heartworm Symposium* 92 231–240.